



Clinical White Paper #1

John (Jeff) Miller, CO
Clinical Services Manager
Wound & Limb Salvage Division



Part I: Defining the Problems

INTRODUCTION

The exact pathogenesis of peripheral neuropathies, Charcot foot degeneration and wound development is often difficult to establish. The potential interactions and progressive nature of the different yet related pathologies remains alarming. The purpose of this two-part clinical white paper is to (I) define the problems and (II) refine the solutions. Topics will include the physiological processes of these three major lower limb involvements, interaction of one physiological process upon the next, key concepts of orthotic treatment, effective orthotic design solutions, and lifespan care programs for the effective long-term management of patients presenting with these conditions.

Peripheral neuropathy

The primary task of the peripheral nervous system is to transmit information from the brain and spinal cord to all parts of the body. It is estimated that more than 20 million Americans suffer from some form of peripheral neuropathy (PN) resulting in dysfunction and disability. Compression, loss of myelin sheaths, disconnection and degeneration are contributing factors to the more than 100 different types of peripheral neuropathy. Each form of neuropathy has its own cause, symptoms, progression and prognosis. The symptoms associated with PN can range from a mild tingling or numbness to excruciating burning pain or even paralysis. The causes of PN are as varied as the symptoms and are listed in Figure 1.

Figure 1. Causes of peripheral neuropathies.

- Alcohol excess
- Medication
- Infections
- Nutritional imbalances
- Hormonal imbalances
- Diabetes
- Autoimmune diseases
- Systemic diseases
- Vitamin deficiencies
- Heredity
- Injury
- Chemotherapy
- Exposure to toxic substances
- Dietary deficiencies
- Vascular disorders
- Kidney disorders
- Tumors

2 IN 100 PEOPLE HAVE SOME FORM OF PERIPHERAL NEUROPATHY

Neuropathies may be sensory, motor or autonomic in nature. **Sensory neuropathies** are accompanied by strange sensations including but not limited to pain, inability to feel pain, tactile disruptions, sensitivity to temperature, lack of coordination, loss of reflexes, numbness, tingling or burning sensations. **Motor neuropathies** produce muscle weakness and loss of muscle control along with decreased balance, incoordination, muscle spasms or cramping, and difficulty moving the affected limbs. **Autonomic neuropathies** can affect the function of organs and glands, breathing, sweating and blood pressure among others. In the most challenging situations, patients may present with a combination of neuropathies that involve disruptions to sensory, motor and autonomic systems.

Diabetes accounts for up to 60% of all peripheral neuropathies while the remaining are idiopathic and secondary to a variety of other causes. In longstanding diabetes and secondary to the loss of protective sensation, joints fail to recognize the abnormal and high forces transferred through them or the altered joint alignments. Continued load bearing during normal daily activities produces repetitive microtrauma to the affected joints and leads to further bone trauma, progression of joint deformities and eventually tissue breakdown. Nerve conduction testing, electromyography, nerve and skin biopsies are used to confirm the diagnosis, while physical therapy, medication, orthoses and lifestyle modifications are recommended to improve overall function. It is important to note that not all peripheral neuropathies result in the development of Charcot joints, however the single most prevalent cause found in Charcot joints is peripheral neuropathy. Clinical management of peripheral neuropathy is outlined in Figure 2.




Figure 2. Clinical management will be discussed in Part II: Refining the Solution

Considerations for orthotic treatment programs include pathogenesis (diabetic, non-diabetic, etc.), degree of dysfunction, deformity, contractures, ligamentous laxity, potential for progression, acute vs. chronic, and prognosis.

Key concepts for orthotic design include controlling and decelerating initial loading, strategic progression of the center of pressure across the plantar surface of the foot during weight bearing, terminal stance strategy, swing phase dorsiflexion assist, and improving balance. **Prevention of progression of functional deficits, joint deformity and repetitive microtrauma is critical.**

Charcot joints

In many cases, peripheral neuropathy is the predisposing factor for the development of a Charcot joint. It is important to note that any pathology accompanied by a loss of sensation may be identified as a causative factor in the pathogenesis. The terminology relating to Charcot joints lacks professional consensus and more than 40 different names have been proposed in the literature. For the purpose of this paper, the combination of signs and symptoms will be referred to as Charcot foot syndrome (CFS). The exact cause of CFS remains disputed, however, a combination of repetitive microtrauma and changes in

the circulation may trigger the resorption of bone and susceptibility to fractures and dislocations. Although CFS was first noted in non-diabetic patients, diabetic patients currently account for the majority of people diagnosed with CFS. The “rocker bottom” foot is a common result of the insidious process of marked deterioration and acquired deformity. (Figure 3)

Charcot foot syndrome is exacerbated by a combination of mechanical, vascular and other physiological factors. CFS involves a non-infectious and destructive process to weight bearing bones and articulations in patients with insensate limbs affected by peripheral neuropathies. The unilaterality of the condition is emphasized in most studies, however bilateral cases are reported in 10% to 30% of patients. Unilateral presentation can also trigger the development of contralateral CFS and/or recurrence on the ipsilateral side.

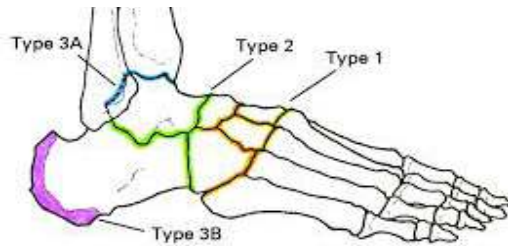
The features of CFS in the affected foot and ankle include distended joints, disorganization, dislocation, debris, increased density and destruction. Clinical findings and presentations are varied based upon the specific course of damage and may result in any combination of fractures (often without pain), ligamentous laxity, cartilage deterioration, dislocations, osteomyelitis, ulceration, infection, instability, bone deterioration and deformity. Brodsky et al proposed an anatomical classification of Charcot foot involvement based upon the affected joint(s). (Figure 4) The midfoot is the most often affected joint in the lower extremity, followed by the hindfoot, ankle, heel, forefoot and combinations.

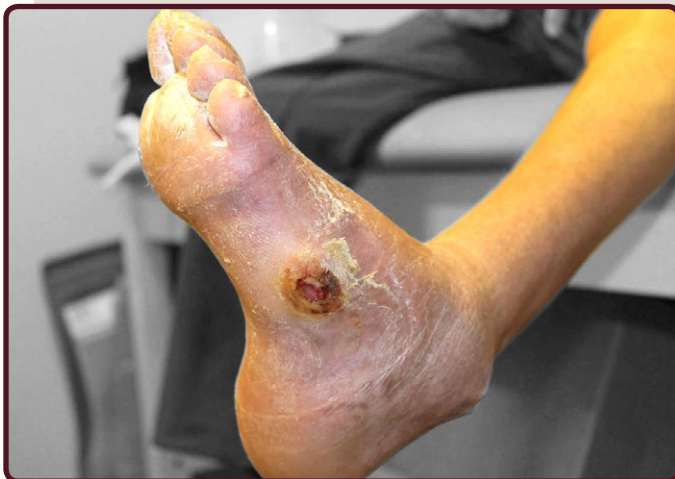

Figure 3. Charcot foot syndrome and rocker bottom foot.

- Charcot joint
- Charcot arthropathy
- Charcot foot • Neuropathic joint
- Neurotrophic joint • Charcot syndrome
- Charcot neuroarthropathy
- Charcot neuropathic osteoarthropathy
- Diabetic neuro-osteoarthropathy

Figure 4. Brodsky anatomic classification of Charcot arthropathy.



Type	Location / % of Patients	Involved Joints
1	Midfoot (60%)	Tarsometatarsal, naviculocuneiform
2	Hindfoot (10%)	Subtalar, talonavicular, calcaneocuboid
3A	Ankle (20%)	Tibiotalar
3B	Calcaneus (< 10%)	Tuberosity fracture
4	Multiple regions (< 10%)	Sequential and concurrent
5	Forefoot (< 10%)	Metatarsophalangeal

Structural abnormalities create exacerbated plantar pressures during loading; hammertoes, claw toes and other foot anomalies are common. The amount of bone

and joint damage is often dependent upon the degree of sensory loss, activity level and degree of disruptions to the mechanical stresses transferred through the joint structures. In the worst scenarios, amputation and even death may occur. (Figure 5)

Although the exact pathophysiological processes are unknown, two major theories exist for the development of Charcot foot syndrome. The neurotraumatic theory proposes that CFS is the result of repetitive microtrauma to an insensate foot. The neurovascular theory proposes that bone resorption is triggered by an inherent vascular reflex and results in deterioration. While the pathogenesis may differ between patients, the sensory-motor neuropathy and autonomic involvement are key factors combined with even moderate stresses (i.e. walking) that serve to initiate this destructive disease process. Fractures, ligamentous laxity, dislocations, damage to cartilage, bone erosions and hypertrophic repair result in severe and progressive deformities.

The true prevalence of CFS is unknown, however, numerous risk factors exist such as: trauma, peripheral vascular disease, diabetes, ulceration, physical activity, excessive plantar pressures, repetitive abnormal loading, obesity, instability, age, contractures and sensory or

Figure 5. Progressive nature of peripheral neuropathy, Charcot foot syndrome and wounds.

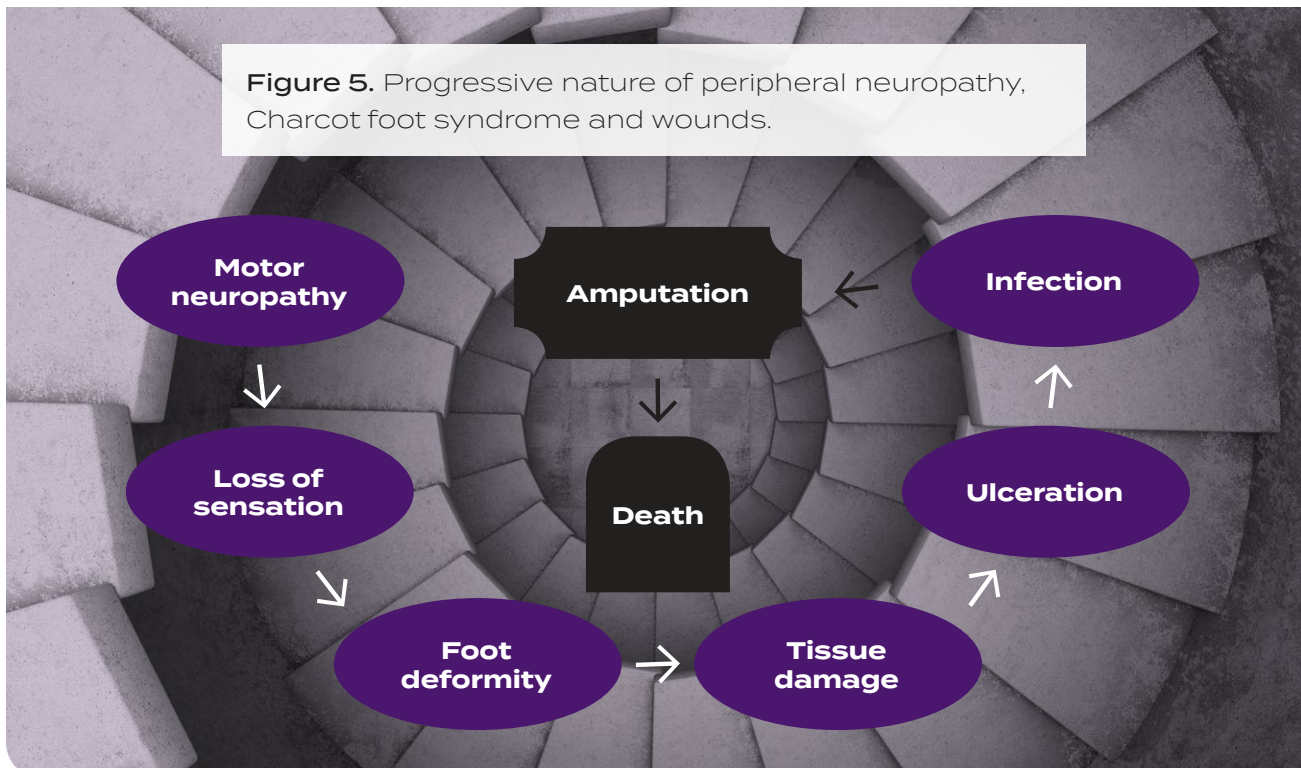
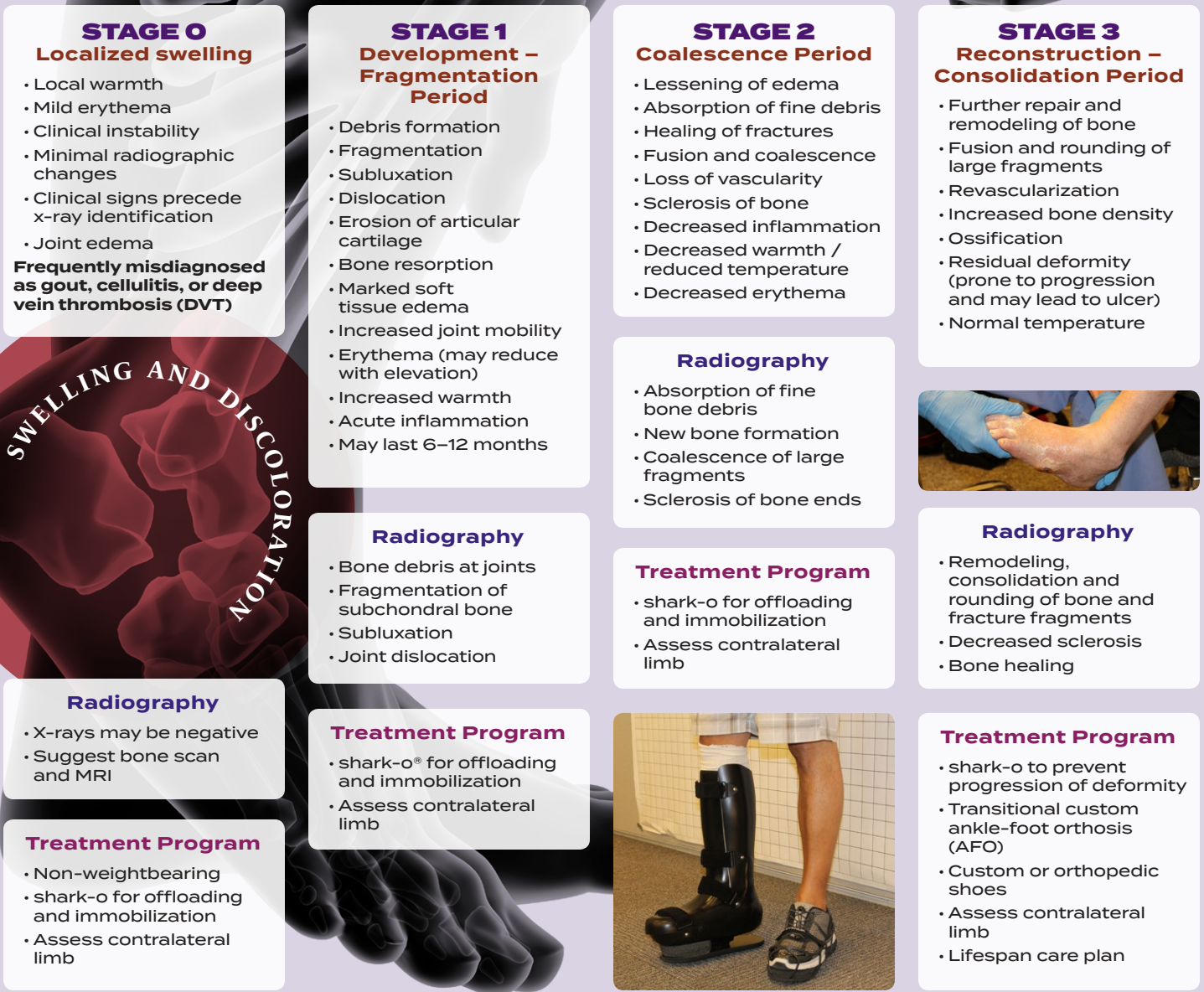

Figure 6. Staging and progression, Eichenholtz (1–3) and Shibata (O)



autonomic neuropathies. Ultimately, any condition or pathology that leads to the development of an insensate foot may be a precursor to the development of CFS. Still, the staging and progression of the disease process proposed by Eichenholtz and Shibata follow a common and predictable path (Figure 6). It is important to note that the acute Stage 0 defined by Shibata is often misdiagnosed in up to 25% of cases as gout, deep vein thrombosis, posterior tibial tendon dysfunction or infection.

As a result, early intervention of Charcot foot syndrome is often delayed until it has progressed into Stage 1 and a definitive diagnosis is made. If acute CFS is suspected, immediate referral to a multidisciplinary foot care clinic is recommended for effective management of this complex condition. **It is important to note that the average duration of the destructive process varies from 2–3 months, however complete healing of the affected Charcot joint(s) may take up to 1–2 years.**

Once the process is initiated, a vicious cycle of destruction continues. Joint deviations lead to abnormal plantar pressures and ongoing microtrauma to the joints. Inflammation triggers osteoclast activation (i.e. pathological bone resorption), leading to lower bone density, fractures, deformity and wounds. Early diagnosis and effective orthotic management are imperative to reduce and avoid the rapid development of permanent foot deformity and the associated complications it presents (e.g. ulcer, difficulty with foot wear, disrupted ambulation ability, etc.) Recurrence rates for CFS vary from 10% to 30%, making the post-treatment transitional orthotic program as important as the initial orthotic design for offloading and immobilization. Ulceration may result from bony deformity or instability, and may lead to chronic or recurrent soft tissue infection or osteomyelitis. Clinical management of Charcot foot syndrome is briefly outlined in Figure 7.

Figure 7. Clinical management will be discussed in Part II: Refining the Solution

Considerations for orthotic treatment programs

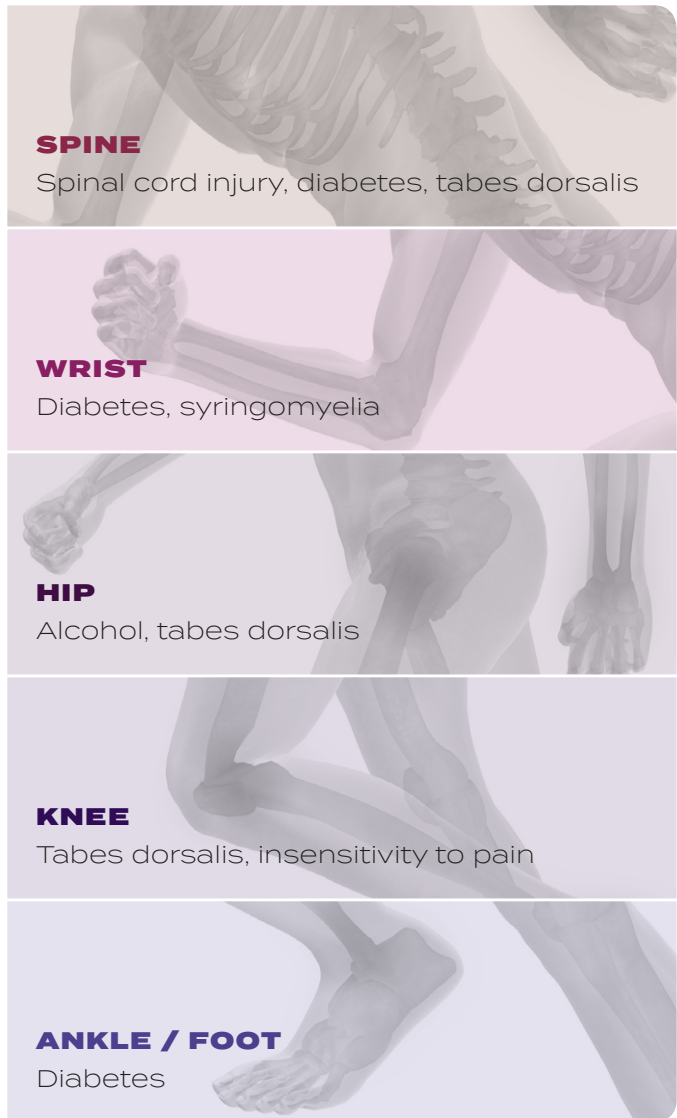include pathogenesis (diabetic, non-diabetic, etc.), location of joint(s) affected, degree of dysfunction, deformity, contractures, ligamentous laxity, potential for progression, acute vs. chronic, potential for wound development, and prognosis.

Preventive care is focused on the contralateral side.

Key concepts for orthotic design not only focus on **OFFLOADING and IMMOBILIZATION** during Stages 0 - 3, but also include controlling and decelerating initial loading, strategic progression of the center of pressure during weight bearing, and improving balance. **Prevention of the progression of joint deformity and repetitive microtrauma is critical.**

Charcot joint destruction may occur anywhere in the body and the location is highly suggestive of the primary diagnosis. Vascular management, infection control and pressure relief must be managed, and considerations for offloading and/or immobilization must occur when appropriate. Ultimately, outcomes will vary depending on the location of the involvement, severity, degree of damage, surgical intervention and compliance with the recommended treatment program. (Figure 8)

Figure 8. Location of Charcot joints and primary pathologies.

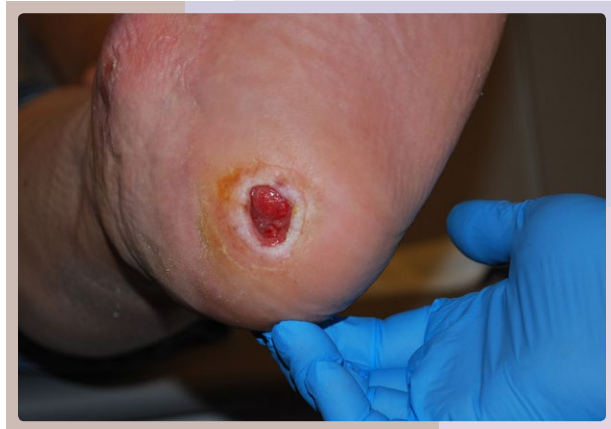

Wounds

Foot ulcers are the result of repetitive stresses from weight bearing, pressures, friction, peripheral neuropathies, structural changes, ischemia, functional deficits (e.g. foot slap) and other factors. These ulcers are especially prone to progression in patients with insensate feet. Even for patients with adequate perfusion, the healing of a foot ulcer will be delayed unless early interventions with effective offloading efforts are employed. After healing, patients still face up to a 40% recurrence rate over the next few months. Wound care clinicians must understand the devastating effects of unresolved pressures, shear forces

and repetitive loading or injury. Effective treatment programs must balance individual patient factors along with the opportunity to provide optimal pressure offloading treatments.

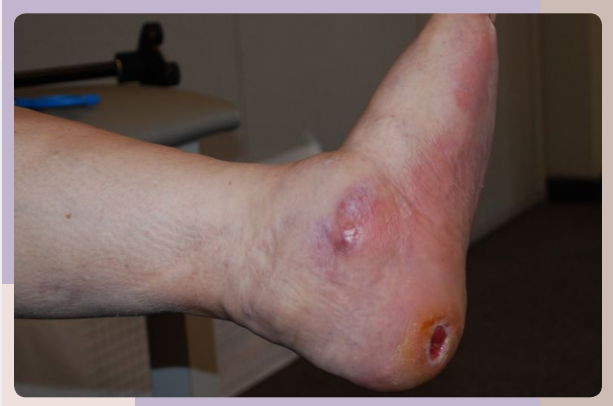Figure 9. Symptoms of foot ulcers.



- Presence or absence of pain
- Swelling of foot
- Bleeding
- Discharge from ulcer
- Difficulty moving foot
- Skin discoloration
- Thickened or hardened areas on the skin

Wounds are especially prevalent in patients with diabetes due to the potential combination of loss of protective sensation, bony deformities, impaired circulation, lack of self-care and obesity that may contribute to ulcer formation. Symptoms of foot ulcers are shown in Figure 9. Prevention is the key to effective management of the diabetic foot, and early intervention with effective multidisciplinary treatment programs is critical. For all patients, determining the appropriate treatment program requires identification of the pathogenesis and causation. Common diagnoses associated with foot wounds include posterior tibial tendon dysfunction, varus and equinovarus deformity, joint instability, Charcot foot syndrome and dropfoot dysfunction. Unresolved pressures, arterial disruptions, ischemia and/or neuropathies may also cause ulcers. Combined with an existing or developing deformity, instability, trauma and/or contracture, patients present very challenging profiles and require the need for unique orthotic management systems. Clinical considerations for diabetic populations are shown in Figure 10.

Figure 10. Clinical considerations for diabetic populations.

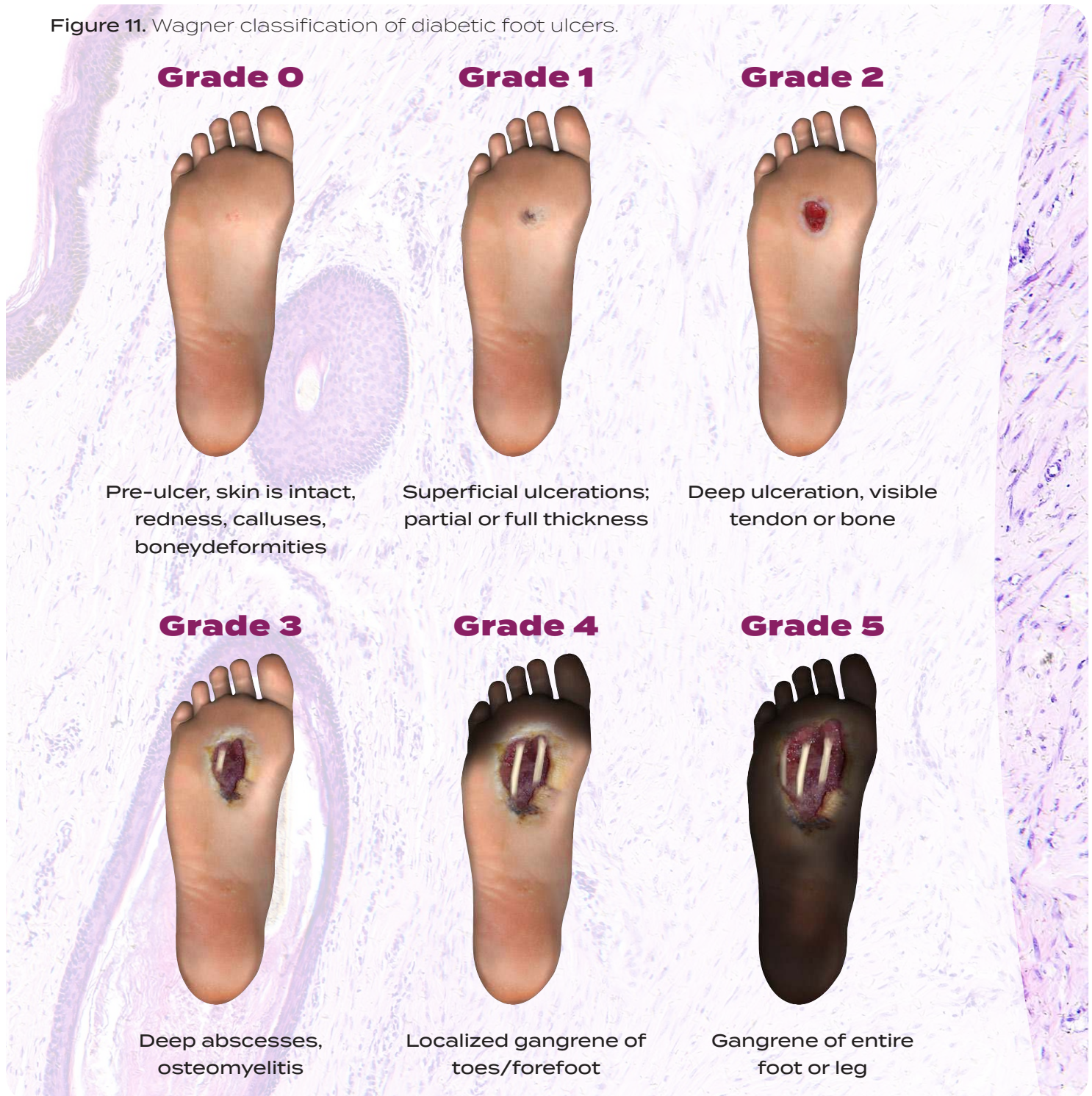

- 30 times more likely to experience a lower limb amputation
- 10 times more likely to be hospitalized for bone and soft tissue infections
- Up to 25% will develop a foot ulcer, 15% will require hospitalization for foot complication, and 20% will require an amputation
- Average cost of a major amputation is \$45,000
- Average cost to heal a single ulcer is \$8,000 to \$10,000; and the average cost to heal an infected ulcer is double
- 40% re-ulceration within the first three years; and 70% re-ulceration over five years
- Approximately 80,000 amputations are performed each year in the US with:
 - ◆ High incidence of recurrence in same area
 - ◆ Up to 50% will develop wounds/ulcers on contralateral side with resultant amputation
 - ◆ High 2–3 year mortality rate after first amputation

While there is no universally accepted wound classification, the Wagner Grade Scale is commonly used to classify the severity of wounds and is summarized on page 8 (Figure 11). Clinical factors include but are not limited to: wound size, wound depth, presence of sinus tracts, probing to bone, amount of granulation tissue, presence of fibrotic or dysvascular tissue, drainage, hyperkeratotic tissue, and signs of infection. With good circulation and consistent medical attention, healing of a superficial ulcer may occur within three to six weeks. Deeper ulcers may take up to 20 weeks to heal. Wounds that do not heal within three months are considered chronic and surgery may be considered. Many patients

experience recurrence of the ulceration, especially those with peripheral neuropathies, abnormal foot pathomechanics and peripheral arterial disease (PAD). While PAD is not a direct cause of the wound, it is a contributing factor to delayed healing.

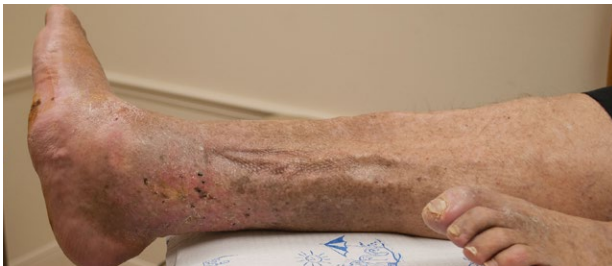Figure 11. Wagner classification of diabetic foot ulcers.



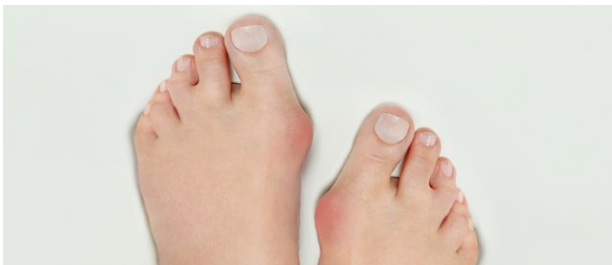Risk factors for the development of ulcers for all patients include foot deformities, obesity, loss of protective sensation, motor neuropathies, and inadequate offloading (Figure 12). Hammertoes, hallux valgus and other foot deformities may result from the medical condition or poor fitting footwear, and may progress with increased pressures and risk the development of ulcers.

The time between the onset of symptoms, diagnosis, and effective treatment may be several weeks or months, during which time the severity of the condition progresses. Wounds evolve and change over time, and effective healing requires dynamic team management with frequent patient follow-up visits. A lifespan care program is necessary to prevent the devastating effects and consequences of tissue damage, ulceration, infection, amputation and even death.

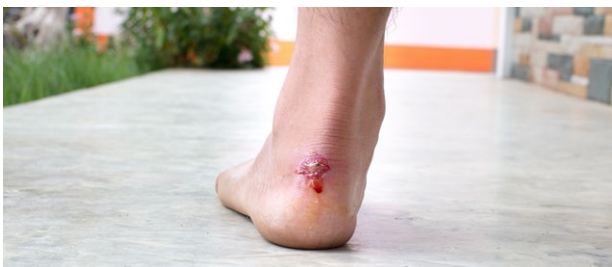Figure 12. Three primary factors associated with diabetic foot ulcers.



Peripheral sensory neuropathy: burning pain, stabbing pain, numbness, sensitivity to touch



Deformity: claw toes, hammer toes, hallux valgus



Trauma: inappropriate footwear, foot slap

Effective medical treatment for peripheral neuropathy, Charcot foot syndrome and foot wounds demands a comprehensive team approach and extensive lifespan care program. Debridement, offloading and infection

control are key treatments to successful healing. Both the wound causation and underlying pathology must be identified and addressed in a comprehensive treatment program. Peripheral neuropathies may be acute or chronic and effective orthotic treatment may prevent the progression to more serious medical conditions. Charcot foot syndrome is especially prevalent in the diabetic population, and immobilization and offloading during the first few months must be followed by protective weight bearing programs for up to two years. Simply allowing the patient to return to previous footwear and walking conditions may trigger the recurrence of the Charcot condition or lead to the development of a new foot wound. The healing time for wounds varies considerably relative to the individual, and post-healing treatment programs must continue indefinitely. (Figure 13.)

Figure 13. Three phases of wound healing.

INFLAMMATORY PHASE

- Up to 3 days
- Bleeding stops
- Inflammation
- White blood cells attack bacteria and debris
- Growth factor stimulation

PROLIFERATION PHASE

- 3 days to 3 weeks
- New blood vessels develop
- Collagen synthesis
- Granulation
- Epithelialization

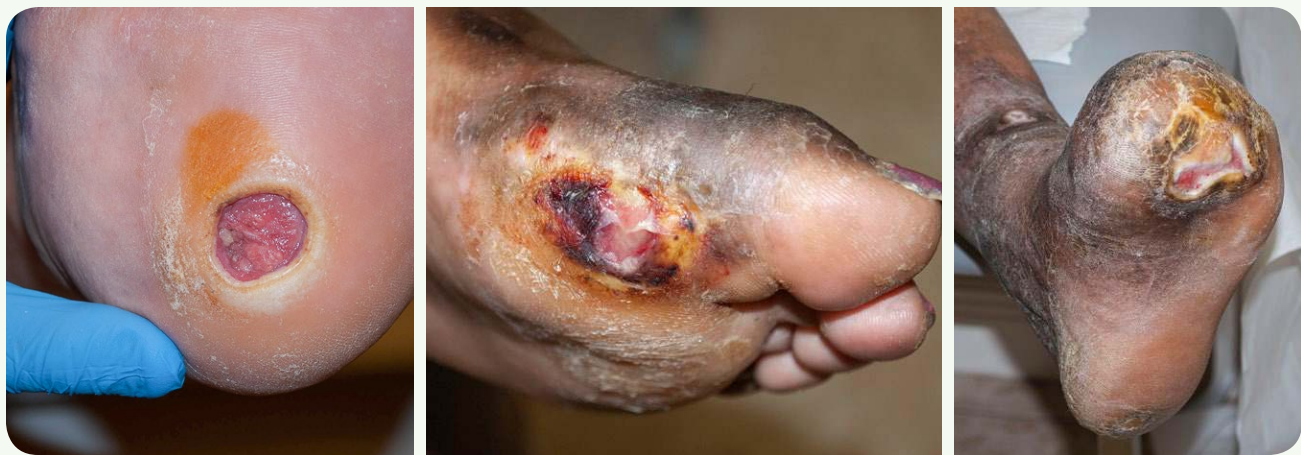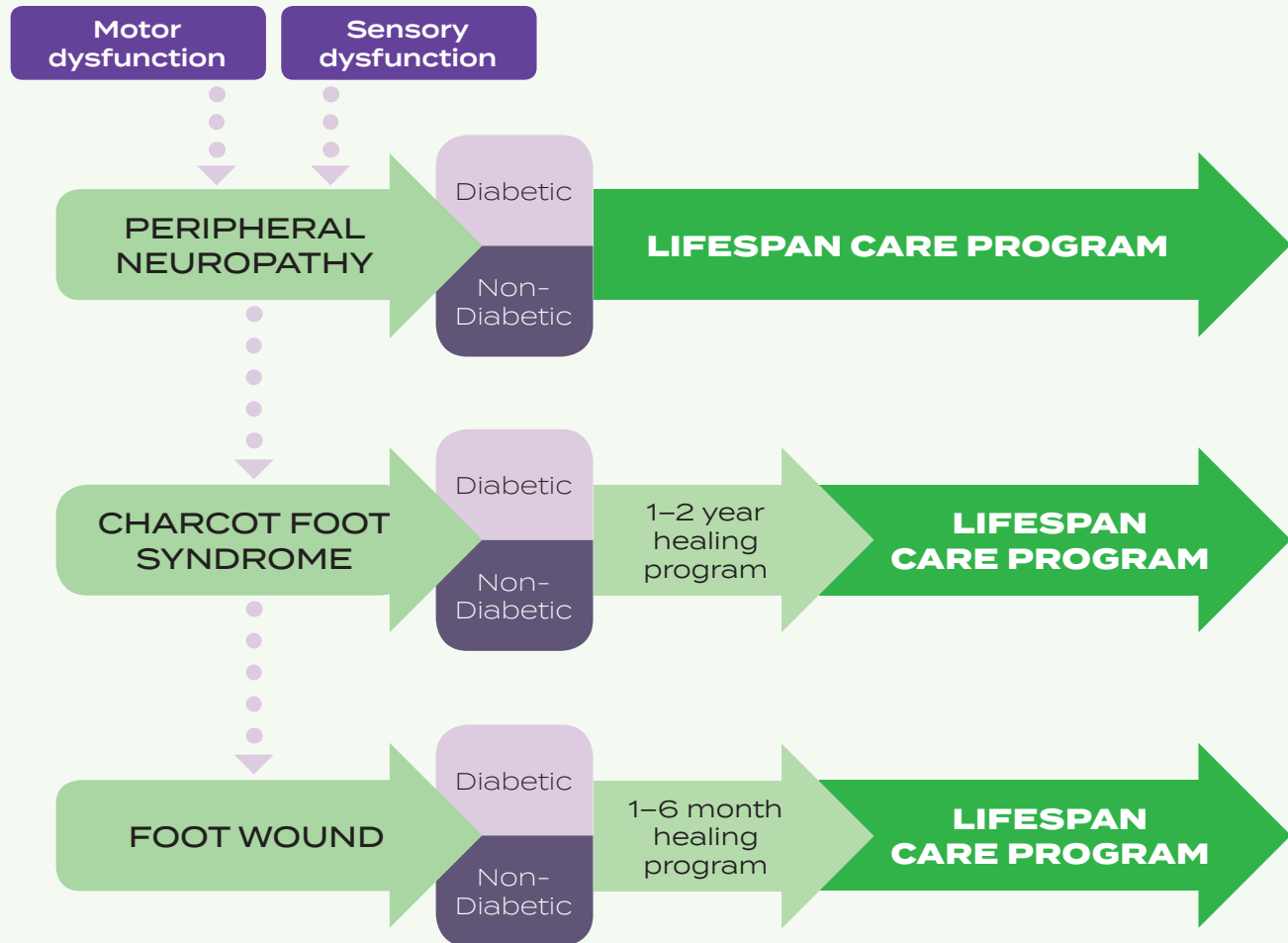
MATURATION PHASE

- Up to 2 years
- Reorganization of collagen

Management may include offloading, daily dressings, debridement, antibiotics, control of blood glucose, and evaluation and correction of peripheral arterial insufficiency. Long-term healing and maintenance strategies must follow initial healing efforts to prevent recurrence of the wound or joint trauma. (Figure 14)

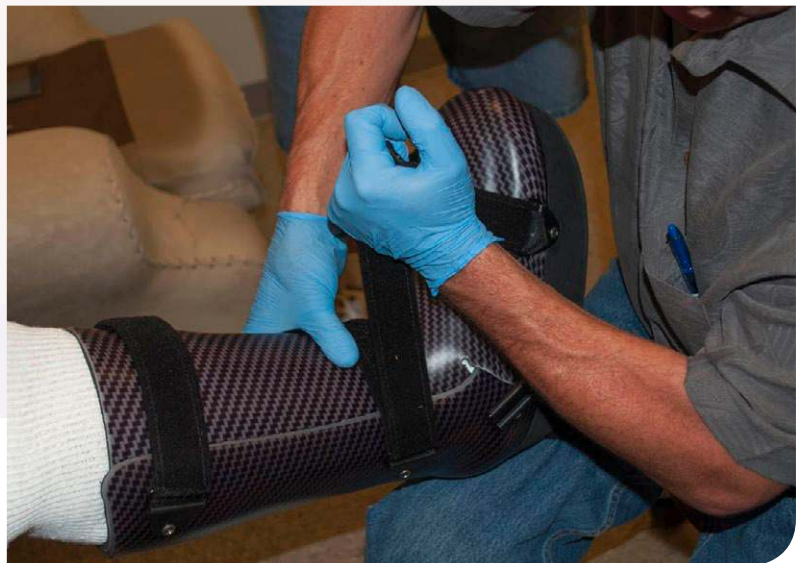Figure 14. The pathogenesis of lower limb dysfunction, deformity and wound development.

PATHOGENESIS



References and Additional Readings

1. *Armstrong DG et al. (2014). Offloading foot wounds in people with diabetes. Wounds, 26(1):13-20.*
2. *Babu V & Bhattacharya B (2017). Charcot joint. <https://radiopaedia.org/articles/charcot-joint>.*
3. *Galhoum AE & Abd-Ella MM (2016). Charcot ankle neuroarthropathy pathology, diagnosis and management: A review of the literature.*
4. *Hanft JR, Hall DT & Kapila A (2011). A guide to preventative offloading of diabetic foot ulcers. Podiatry Today, 24(12).*
5. *Kaynak G et al. (2013). An overview of the Charcot foot pathophysiology. Diabet Foot Ankle, 4:10.3402/dfa.v4i0.21117.*
6. *Milne TE et al. (2013). Developing an evidence-based clinical pathway for the assessment, diagnosis and management of acute Charcot neuro-arthropathy: A systematic review. J Foot Ankle Research, 6:30.*
7. *Mrdjenovich DE (2010). Offloading practices for the wounded foot: Concepts and choices. J Am Col Certif Wound Spec, 2(4):73-78.*
8. *Pietrangelo A & Morrison W (2016). Idiopathic neuropathy. www.healthline.com/health/idiopathic-neuropathy#symptoms2.*
9. *Rogers LC et al. (2011) The Charcot foot in diabetes. Diabetes Care, 34(9):2123-2129.*
10. *Schade VL & Andersen CA (2015). A literature-based guide to the conservative and surgical management of the acute Charcot foot and ankle. Diabetic Foot & Ankle, 6(1).*





ORTHOMERICA[®]
www.orthomerica.com/owls
(877) 737-8444 • custserv@orthomerica.com